

## 2<sup>nd</sup> International Conference

# HUS-MPGN-PNH

## Current diagnosis and therapy of thrombotic microangiopathies: hemolytic uremic syndrome (HUS), membranoproliferative Glomerulonephritis (MPGN) and paroxysmal nocturnal Hemoglobinuria (PNH)

### Abstract form (in English)

#### Title (in capitals)

#### REMISSION OF PLASMA-RESISTANT ATYPICAL HEMOLYTIC UREMIC SYNDROME RELAPSE ON KIDNEY GRAFT WITH ECULIZUMAB

#### Authors//Institution/ Department

G Ardissino, S Testa, F Paglialonga, M Belingheri, L Ghio, A Sogliani, N Borsa-Ghiringhelli, S Tedeschi, S Salardi, P Castorina and A Edefonti.

#### Text

#### Structure:

The aim of the study

Methods

Results

Conclusion

Please, type using the **Times**

**New Roman, large 12**

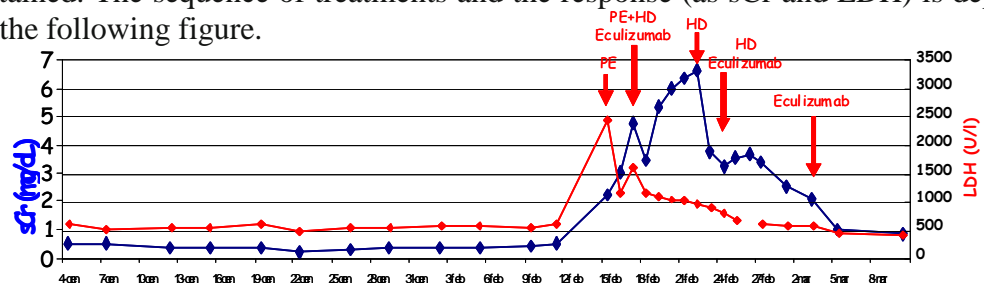
#### To be sent to:

Prof. LB. Zimmerhackl,  
Dptm. of Paediatrics  
Anichstraße 35. A-6020  
Innsbruck, using the E-mail  
and parallelly the air/surface  
mail, **dead-line May 3,  
2010!**

Center for HUS Control, Fondazione IRCCS Ca' Granda - Osp Maggiore Policlinico, Milan, Italy.

**Aim of the study:** Atypical hemolytic uremic syndrome (aHUS) has been associated with genetic defective regulation of the alternative complement pathway and tends to recur after kidney transplantation. Plasma exchange is an effective first line therapy but some cases are resistant. Eculizumab, a monoclonal humanized anti-C5 antibody, inhibits activation of the terminal complement pathway and has been repeatedly shown to be effective in patients with aHUS.

**Methods and Results:** We report on a patient with aHUS due to Factor H mutation whose disease recurred 2 months after kidney transplantation from cadaver donor and that was successfully treated with Eculizumab. A 6 year old boy with CKD-V for aHUS due to the factor H mutation p.[Ser1191Leu; Val1197Ala] underwent kidney transplantation, from cadaver donor with plasmaexchange before and after transplantation (for the first 40 days) according to a specific protocol previously reported (Ped Nephrol 2008;23:1688). Immunosuppressive protocol included basiliximab, cyclosporine and prednisone. Two months after transplantation, with normal renal function (sCr: 0.47 mg/dL) during regular (once weekly) fresh frozen plasma (FFP) infusion (15 mL/kg) HUS recurred in absence of concomitant illness. Two plasmaexchanges (150% plasma volume) with FFP did not send the disease into remission and Eculizumab (600 mg) was administered and instant remission was obtained. The sequence of treatments and the response (as sCr and LDH) is depicted in the following figure.



**Conclusions:** We conclude that Eculizumab is safe and effective in inducing remission of in relapses of aHUS on kidney transplant resistant to plasma.

Supported by a research grant from "Progetto ALICE ONLUS Association patient of HUS Italy".